

GUNDERSEN HEALTH SYSTEM ULTRASOUND DEPARTMENT POLICY AND PROCEDURE MANUAL

SUBJECT: **Portal and Hepatic Venous Duplex Ultrasound**
 SECTION: **Vascular Ultrasound**
 ORIGINATOR: **Kraig Schuster**
 REVISED DATE: **December 19, 2018**

APPROVED BY:

 Jody Riherd MD

 Dave Clayton RDMS RVT

Prep: NPO 12 hours prior to exam.

Patient Position: Supine with right lateral decubitus and left lateral decubitus as needed.

Equipment: Colorflow duplex ultrasound unit with 3.5 MHz and/or 2.5 MHz curved linear or phased array transducers. *****Procedure should be performed at the lowest possible power settings.**

Purpose: _

Portal Hypertension
 Portal, splenic, and/or superior mesenteric vein thrombosis
 Budd-Chiari syndrome
 Hepatic vein occlusive disease
 Portal/hepatic vein flow abnormality by congestive heart failure

Exam Protocol:

A “modified” complete abdominal ultrasound exam is performed in conjunction with the abdominal Doppler exam. See the RUQ exam protocol and page 4 of this protocol.

Splenic Vein

Patient supine. Midline transverse orientation. Located posterior the pancreas and courses towards hilum of the spleen. Normally continuous hepato-petal flow pattern into the main portal vein.

Superior Mesenteric Vein (SMV):

Patient supine. Midline longitudinal orientation. Located near the head of the pancreas. Normally continuous hepato-petal flow pattern into the main portal vein.

Portal Vein

Patient supine and/or left lateral decubitus. Originates at the confluence of the SMV and splenic vein. Normally continuous hepato-petal flow pattern with variations induced by respirations. Bifurcates into the right and left portal veins. The right portal vein then bifurcates into the right anterior and right posterior portal vein. Attention should be placed on evaluation of the left portal vein for a dilated paraumbilical vein. The right portal vein is usually best imaged in a left lateral decubitus position, using the liver as an acoustic window.

Hepatic Veins

Supine and/or left lateral decubitus. Normally complex hepato-fugal flow pattern into the inferior vena cava. Flow varies with changes in respiration, abdominal pressure, and right atrial pressure. The right hepatic vein (HV) is often best imaged with the patient in the left lateral decubitus position through a lateral intercostal approach. The middle and left hepatic veins are best imaged from a transverse subcostal approach with the patient supine.

Collateral Pathways

Portal hypertension will divert the systemic venous circulation through multiple collateral pathways.

Dilated Paraumbilical Vein: Extends from the left portal vein to the umbilicus. Normally does not have any detectable flow. Hepato-fugal flow when dilated.

Gastroesophageal Collaterals: Seen along the posterior aspect of the left lobe of the liver, near the gastroesophageal junction. Normally does not have any detectable flow.

Coronary Vein: Best seen with a longitudinal view at the junction of the SMV and main portal vein. Extends cephalad from the portal vein. Normally does not have any detectable flow. If flow is detected it is normally hepato-petal. Dilatation to > 0.7 cm is associated with severe portal hypertension.

Splenorenal shunts: Seen near the splenic hilum, flowing towards the left renal vein. Normally does not have any detectable flow.

Diagnostic Criteria for Portal and Hepatic Circulation:

I. Real time examination should be performed evaluating the upper abdominal organs for size, echotexture, focal masses, or juxtaposed abnormalities.

II. The Doppler Examination:

A. Normal exam.

1. Portal veins (RPV, LPV, and MPV), SMV and splenic veins, spectral waveform demonstrates hepatopetal flow with a monophasic low velocity wave form which undulates slightly with respiration.
2. No varicies should be demonstrated.
3. Hepatic veins spectral waveform is pulsatile and is characterized by both forward and reverse flow components caused by fluctuations in the right atrial pressure during the cardiac cycle.

B. Abnormal exam

1. Portal Hypertension.
 - a. The spectral waveform may become biphasic or demonstrate hepatofugal flow.
 - b. Collaterals may be present in the paraumbilical region, coronary vein region, gastroesophageal junction and/or near the area of the spleen and left kidney.
2. Portal vein occlusion.
 - a. Acute: demonstrates an enlarged vein and intraluminal material on gray scale imaging. Doppler findings consist of absence of spectral or color flow. The occlusion may be partial. It is important that the Doppler technique uses an appropriate angle and has the setting appropriate for evaluating deep slow flow.
 - b. Chronic: findings can be represented by cavernous transformation of portal vein (multiple collateral vessels near the porta hepatis).
3. Hepatic Vein abnormalities
 - a. Budd-Chiari Syndrome – sonographic findings include echogenic intraluminal thrombus or tumor, absence of hepatic vein flow or localized flow disturbance caused by partial obstruction.
 - b. Note that there may be secondary flow disturbance caused by partial obstruction.
 - c. Note that there may be secondary flow abnormalities in the portal veins including a biphasic or even reversed portal flow.
 - d. The IVC may be the cause of Budd-Chiari Syndrome and tumor or thrombus within the IVC should be sought.
4. Hepatic venous congestion
Right heart failure or tricuspid regurgitation may cause dilated intrahepatic veins. The spectral waveform may become abnormal. See examples.

C. See attached waveforms.

Imaging Protocol:

Additional images may be necessary to adequately demonstrate anatomy and pathology. Whenever possible, the gray scale images should be performed first and separately from the color and spectral Doppler images.

Gray Scale Images

Transverse liver with all hepatic veins: take more than one image if necessary to be sure all three hepatic veins are imaged

Transverse image of the liver with the portal vein

Longitudinal liver with images to include:

- left lobe of liver with prox. aorta
- left lobe of liver with left portal vein
- liver with IVC labeled
- right lobe of liver with right portal vein
- right lobe of liver/right kidney interface

Gallbladder: Two images longitudinal supine and one transverse supine with GB wall measured; two images longitudinal LLD and one transverse LLD

Long CHD with internal diameter measured

Long CBD with internal diameter measured

Bilateral lung bases to evaluate for pleural effusion(s)

Splenic volume

Four quadrant evaluation for ascites

Color and Spectral Doppler Images

Splenic Vein with color and angle corrected spectral Doppler **at both the splenic hilum and transversely posterior to the pancreas**

Superior Mesenteric Vein with color and angle corrected spectral Doppler

Portal Vein

Main portal vein with color and angle corrected spectral Doppler

Right portal vein with color and angle corrected spectral Doppler

Right portal vein bifurcation colorflow image showing right anterior and right posterior branches

Left portal vein with color and angle corrected spectral Doppler

Hepatic Artery with color and angle corrected spectral Doppler (this image can be obtained wherever the hepatic artery is best visualized)

Hepatic Veins and IVC

IVC with color and angle corrected spectral Doppler

Right hepatic vein with color and angle corrected spectral Doppler

Mid hepatic vein with color and angle corrected spectral Doppler

Left hepatic vein with color and angle corrected spectral Doppler

Collateral Pathways evaluate and document if present with color and angle corrected spectral Doppler

Images should be taken of each area with color Doppler as documentation of evaluation

Paraumbilical vein

Gastroesophageal varicities

Coronary vein

Splenorenal shunts

References:

1. Withers CE, Wilson SR: The Liver. *In* Rumack CM, Wilson SR, Charbonneau JW (ed.): Diagnostic Ultrasound, Vol. 1, 1991. Pp. 45-86.
2. Merritt CR. Doppler Assessment of the Abdomen. *In* Rumack CM, Wilson SR, Charbonneau JW (ed.): Diagnostic Ultrasound, Vol. 1, 1991. Pp. 315-351.
3. Koslin DB, Mulligan SA, Berland LL: Duplex Assessment of the Portal Venous System and the Splenic Vasculature. *In* Zwiebel WJ (ed.): Introduction to Vascular Ultrasonography, 3rd Ed. 1992, pp. 367-385.
1. Sonographic Diagnosis of Hepatic Vascular Disorders, William Zwiebel. Seminars in Ultrasound, CT, and MR, volume 16, #1 (February), 1995, pg. 34-48.
2. Pulsatile Portal Vein Flow: A Sign of Tricuspid Regurgitation on Duplex Doppler Sonography. AJR 155L785-788, October 1990.
3. Pulsatile Portal Vein in Cases of Congestive Heart Failure, Radiology 176: 655, 1990.

PORTAL VENOUS DOPPLER WORKSHEET

Name: _____ MRN: _____ Date: _____

Indication: _____

Ordering Doctor: _____

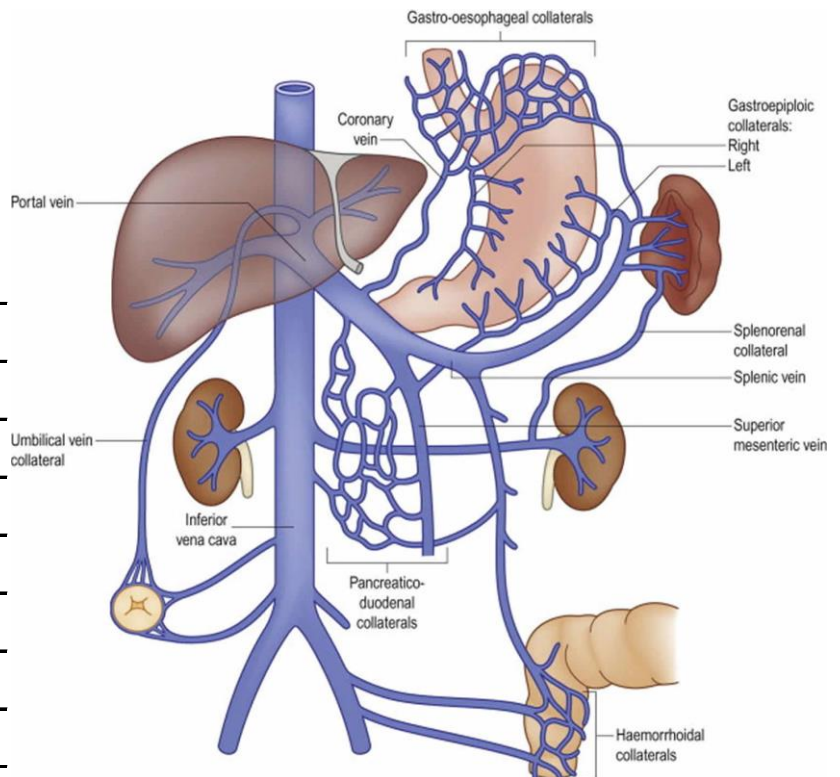
PORTAL	Flow direction		Thrombosis		Waveform		Not seen/Explanation of Findings
	Petal	Fugal	Yes	No	Normal	Abnormal	
MPV							
LPV							
RPV							
SMV							
SPLENIC V							

HEPATIC	Stenosis		Occluded		Waveform		Not seen/Explanation of Findings
	Yes	No	Yes	No	Normal	Abnormal	
RHV							
LHV							
MHV							
Hep Art							
IVC							

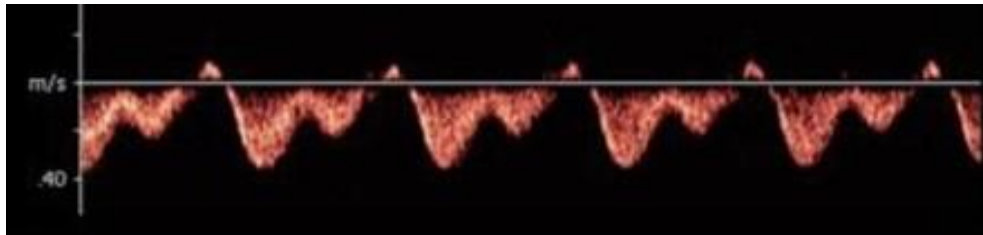
VARICES	YES	NO
PARAUMBILICAL		
CORONARY		
GE JUNCTION		
SPLENORENAL		
OTHER		

Real time findings/Impression:

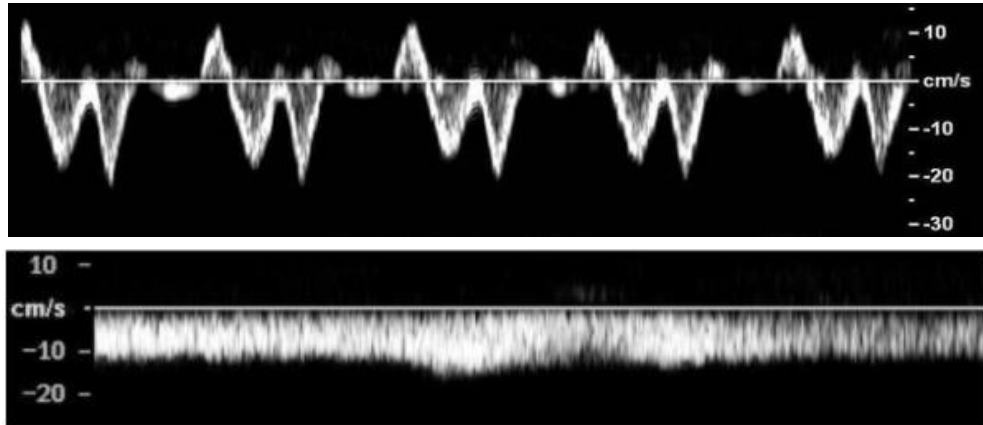
Sonographer: _____



NORMAL HEPATIC VEIN WAVEFORM

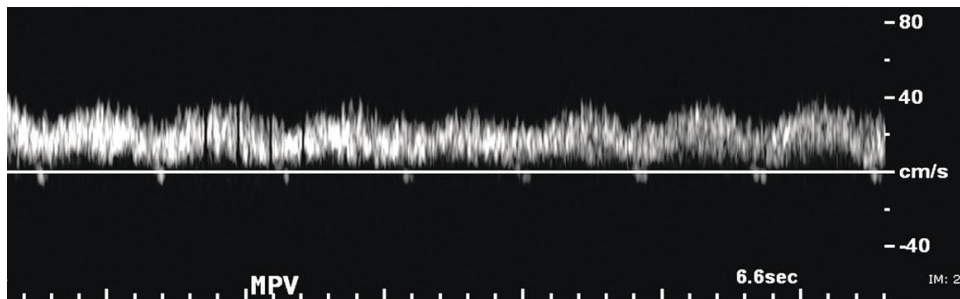


ABNORMAL HEPATIC VEIN WAVEFORM



Abnormal hepatic vein duplex images consistent with tricuspid heart valve regurgitation and cirrhosis
<https://www.birpublications.org/doi/epub/10.1259/bjr/15227254>

NORMAL PORTAL VEIN WAVEFORM

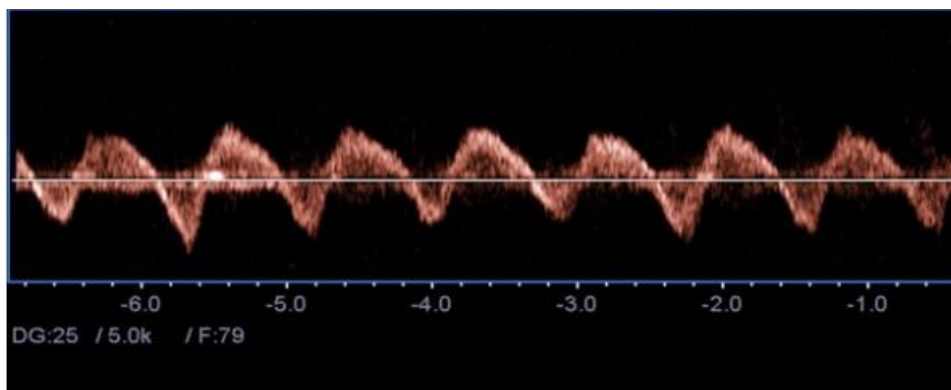


Typical portal vein flow pattern, with fairly uniform velocity and slight phasic variations due to respiration and cardiac motion.

May 2008 RadioGraphics, 28, 691-706

<https://thoracickey.com/ultrasound-evaluation-of-the-portal-and-hepatic-veins-2/>

ABNORMAL PORTAL VEIN WAVEFORM



Pulsatile waveform most commonly seen with tricuspid regurgitation and is suggestive of underlying congestive heart failure

The Internet Journal of Radiology 2009: Volume 9 Number 2

<https://radiopaedia.org/cases/cirrhosis-8?lang=us>