

## SCOLIOSIS – BEND VIEWS

**ROUTINE:** AP side bend views. Scoliosis exams should only be done at sites that have a long scoliosis cassette or that can stitch DR images.

**DISTANCE:** 60", 72" or 84" - depending on the size of patient

**BUCKY:** YES

**FOCAL SPOT:** Large

**IMAGING PLATE:** CR Scoliosis Cassette or Stitched DR images

**CENTRAL RAY:**

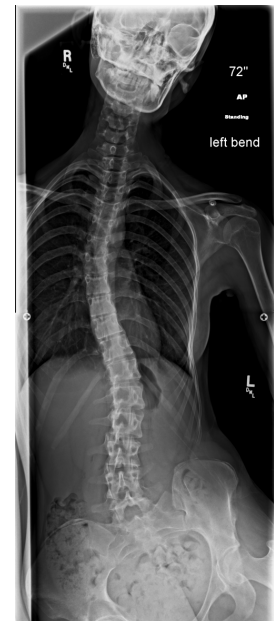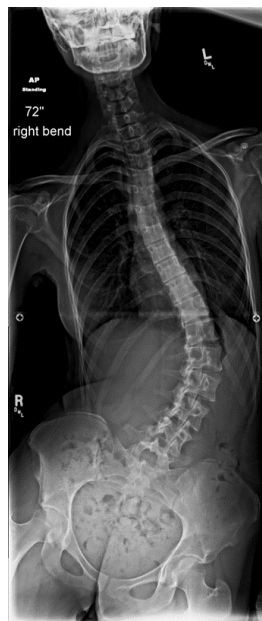
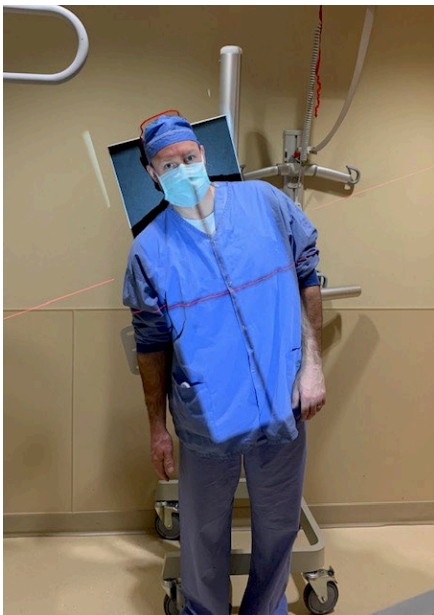1. Perpendicular to the film centered on mid entire spine.

**HELPFUL POSITIONING:**

Make sure patient removes shoes. Position them AP with top of cassette above top of ear. Need to see SI joints. Chin up slightly. Have patient bend sideways, reaching for side of knee. Measure through the lower T-Spine area.

**ADDITIONAL COMMENTS:**

1. Do both left and right bends.
2. If patient is very flexible, you may need to tilt cassette diagonally to include entire spine.



*Updated 01/24/2022 rsj*