

# Head Spiral 0-18 mos.

Siemens go.All

Application Examples: headache, stroke, brain tumor, abscess

Oral Contrast	No
IV Contrast / Volume	*If requested Omnipaque 300 per ped protocol
Injection Rate	Bolus all before topogram

### Technical Factors

Care Bolus ROI Location / HU	N/A
Monitoring Delay	N/A
Cycle Time	N/A
Scan Delay	2 sec (5 minutes if enhanced)
Breath Hold	N/A

Detector Collimator	Acq 32 x 0.7mm
X-Care	Off
kV	100 kV
Eff. mAs	152 mAs
Rotation Time	0.5
Pitch	0.6
CTDIvol	19.33

Topogram: Lateral, 256 mm

Head	Recon Type	Width / Increment	Algorithm	Safire	Window	FOV	Series Description	Networking	Post Processing
Recon 1	Axial	5 x 5	Hr40	3	Cerebrum	200	AXIAL	PACS	None
Recon 2	Axial	3 x 3	Hr60	3	Bone	200	AXIAL BONE	PACS	None
Recon 3	3D: Axial	5 x 5	Hr40	3	Cerebrum	200	AXIAL MPR	PACS	Axial MPR
Recon 4	3D: COR	3 x 3	Hr40	3	Cerebrum	200	COR	PACS	Coronal MPR
Recon 5	3D: SAG	3 x 3	Hr40	3	Cerebrum	200	SAG	PACS	Sagittal MPR
Recon 6	Axial	0.6 x 0.6	Hr36	3	Cerebrum	200	AXIAL 0.6 STND	TeraRecon	None

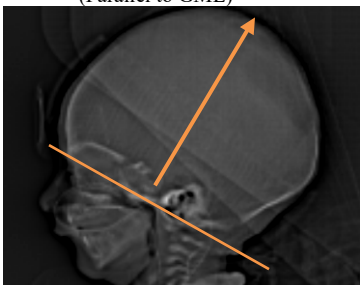
**Patient Position:** Position head as best as possible so the GML is perpendicular to the table in a symmetrical position (no rotation or tilt). Note gantry angle is not possible on the Definition. Axial MPR images should be parallel to a line drawn from the base of the skull to the glabella.

**Scan Range:** Scan from skull base through vertex in caudocranial direction.

**Recons and Reformations:** If patient is not scanned in an orthogonal plane to brain, an axial MPR (Recon 3) is made. Images are created in examination card using raw data and should be parallel to a line drawn from the base of the skull to the glabella.

**3D's:** Include 3D VR on all pediatric heads for trauma under 2 years old. See 1a. PP(3D)CT Pediatric Head for Trauma.

Axial MPR  
(Parallel to GML)



\*If IV contrast enhancement is requested, inject contrast bolus 5 minutes prior to scanning. Enhancement application examples include: tumor, metastatic disease, abscess, or if an MRI cannot be done.