

Bony Pelvis

Siemens Flash

Application Examples: fracture

Oral Contrast	No
IV Contrast / Volume	No

Patient Instructions	Hold Breath
----------------------	-------------

Technical Factors

Detector Collimator	Acq 128 x 0.6 mm
Care kV	On / 120 kV
Care Dose 4D	On / 250 mAs
Rotation Time (seconds)	0.5
Pitch	0.8
Typical CTDIvol	16.88 mGy \pm 50%

Topogram: Lateral & AP, 512 mm

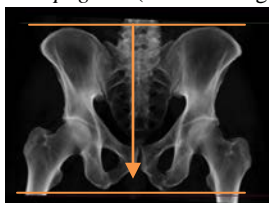Pelvis	Recon Type	Width / Increment	Algorithm	Safire	Window	Series Description	Networking	Post Processing
Recon 1	Axial	3 x 1.5	I70h	2	Bone	AXIAL BONE	PACS	None
Recon 2	Axial	3 x 1.5	I41f	2	Abdomen	AXIAL STND	PACS	None
Recon 3	3D:COR	3 x 3	I30f	2	Bone	COR	PACS	Coronal MPR
Recon 4	3D:SAG	3 x 3	I30f	2	Bone	SAG	PACS	Sagittal MPR
Recon 5	Axial	0.6 x 0.6	I30f	2	Abdomen	AXIAL 0.6 STND	TeraRecon	None

CT scans of the bony pelvis are most often obtained in the setting of an acute trauma. This protocol is designed to examine the cortex of the pelvic ring and acetabuli. Note that data originally obtained for a soft tissue pelvis (e.g. as part of a trauma series) can be reconstructed and reformatted to a bony pelvis providing the raw data is still available.

Position: Patient supine, feet first with legs flat on the table (no cushions or wedges).

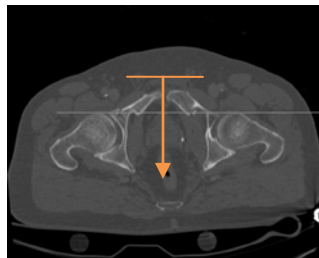
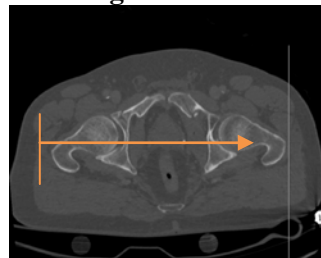
Scan Range: Scan from above iliac crests (IC) through ischial tuberosities including all fracture(s).

AP Topogram (scan coverage)



Recons: Axial images displayed in bone and soft tissue windows through entire pelvis.

Reformations: Align all three view ports in true orthogonal planes before making reformations. If patient is not in ideal position, create a true axial MPR data set.

Coronal MPR**Sagittal MPR**

3D: Upon request. See post processing protocol.