

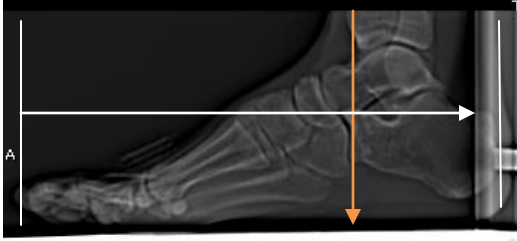Foot

Application Examples: fracture, lisfranc joint injury	
Scan Protocol (See for Technical Factors)	Lower Extremity

Patient Position: Patient lying in supine position, feet first. Lower extremity of interest extended on foot holder with foot perpendicular to table. Opposite leg should be bent at knee and placed out of scan range.

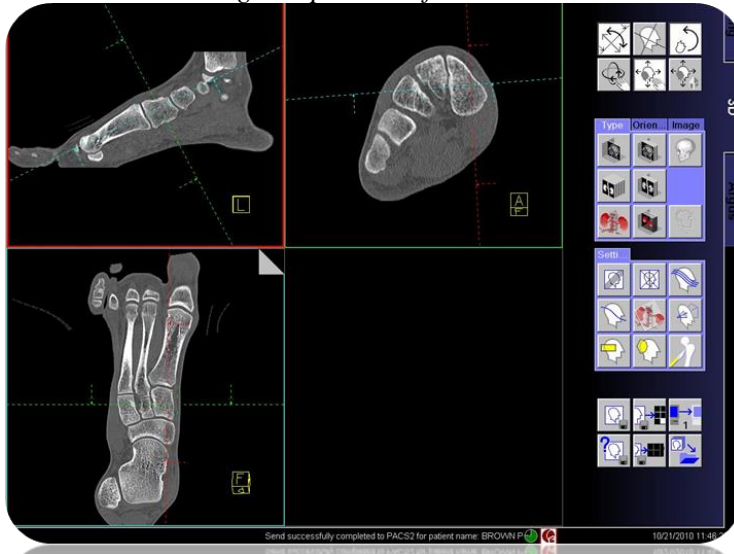
Scan Range: Above tibia/fibula joint through entire foot including entire fracture if applicable.

Area of Coverage on Lateral Topogram

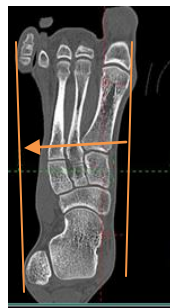

2D Reformations: Align all three viewports to true orthogonal planes before making reformations. Make coronal, sagittal, and axial oblique MPRs as depicted below using thin data set with sharp kernel.

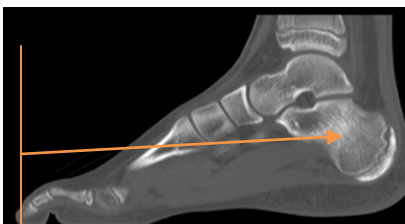
Orthogonal planes to foot



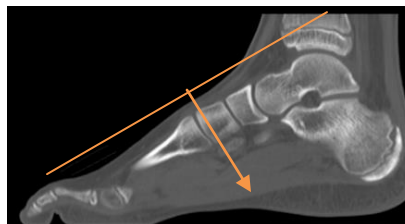
Sagittal MPR
2x2 mm



Coronal MPR
2x2mm



Oblique Axial MPR
2x2 mm



3D: Upon request.