

CT Clavicle

Application Examples: fracture

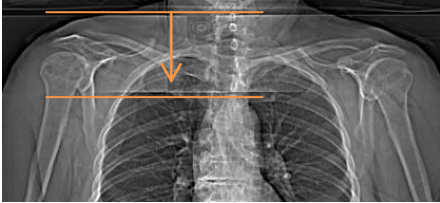
Scan Protocol (See for Technical Factors)

Shoulder

Patient Position: Patient supine, head first, with arms at sides.

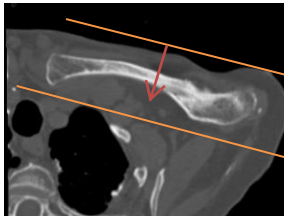Scan Range: Entire clavicle of interest as depicted below.

AP Topogram (scan coverage)

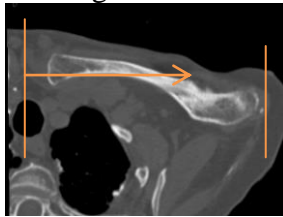


2D Reformations: 2x2 mm coronal, sagittal, and oblique axial MPRs. Use the oblique axial view to plan the coronal and sagittal MPRs and the coronal viewport to plan the oblique axial MPR.

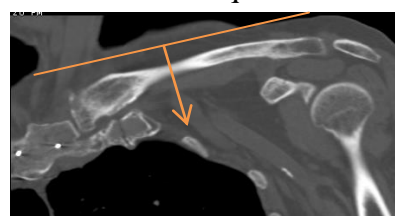
Coronal MPR



Sagittal MPR



Axial Oblique MPR



Series Descriptions: COR
SAG
OBL AXIAL

3D: Upon request.