

## ***GUNDERSEN/LUTHERAN ULTRASOUND DEPARTMENT POLICY AND PROCEDURE MANUAL***

---

SUBJECT: Cervical Node Mapping Ultrasound Exam  
SECTION: Radiology Ultrasound  
ORIGINATOR: Deborah L. Richert, BSVT, RDMS, RVT  
Christy Weisenberger, RDMS  
DATE: September 13, 2013

APPROVED BY: \_\_\_\_\_  
Jody Riherd MD

\_\_\_\_\_  
Dave Clayton RDMS RVT

**Equipment:** Ultrasound unit with at least a 12 to 15 MHz linear transducer.

**Exam Protocol:** With ultrasound the thyroid bed and adjacent soft tissues of the neck will be thoroughly evaluated for masses, enlarged and/or abnormal lymph nodes (see below), thrombosed veins, or any other incidentally detected abnormalities.

**Documentation:** Even though only specific images are documented, all soft tissues of the neck will be scanned in detail. The following images will represent the cervical node mapping ultrasound exam (additional images may be necessary for proper documentation).

- Image the right side of the neck transversely from superior to inferior, zones 1 through 7. As abnormal node(s) are seen measure the node(s) in the transverse orientation first, then immediately measure the node(s) in the longitudinal orientation. Continue imaging the right side of the neck transversely until completely evaluated, zones 1 through 7.
- Image the left side of the neck transversely from superior to inferior, zones 1 through 7. As abnormal node(s) are seen measure the node(s) in the transverse orientation first, then immediately measure the node(s) in the longitudinal orientation. Continue imaging the left side of the neck transversely until completely evaluated, zones 1 through 7.
- Image all abnormal node(s) seen in the neck/thyroid bed with transverse and longitudinal measurements.

When evaluating lymph nodes be aware of the following: nodes that are round (instead of oblong), have focal bulges, or in which the normal hilum is replaced are considered suspicious lymph nodes. Abnormal lymph nodes should be measured in 3 dimensions: longitudinal, transverse, and AP. Note should be made of the location of the lymph node(s) in the correlating zone.

Abnormal lymph nodes should be evaluated for the following characteristics. Please refer to the chart below to determine which node(s) to evaluate. Suspicious features include microcalcifications, hypoechogenicity, irregular margins, and internal vascularity.

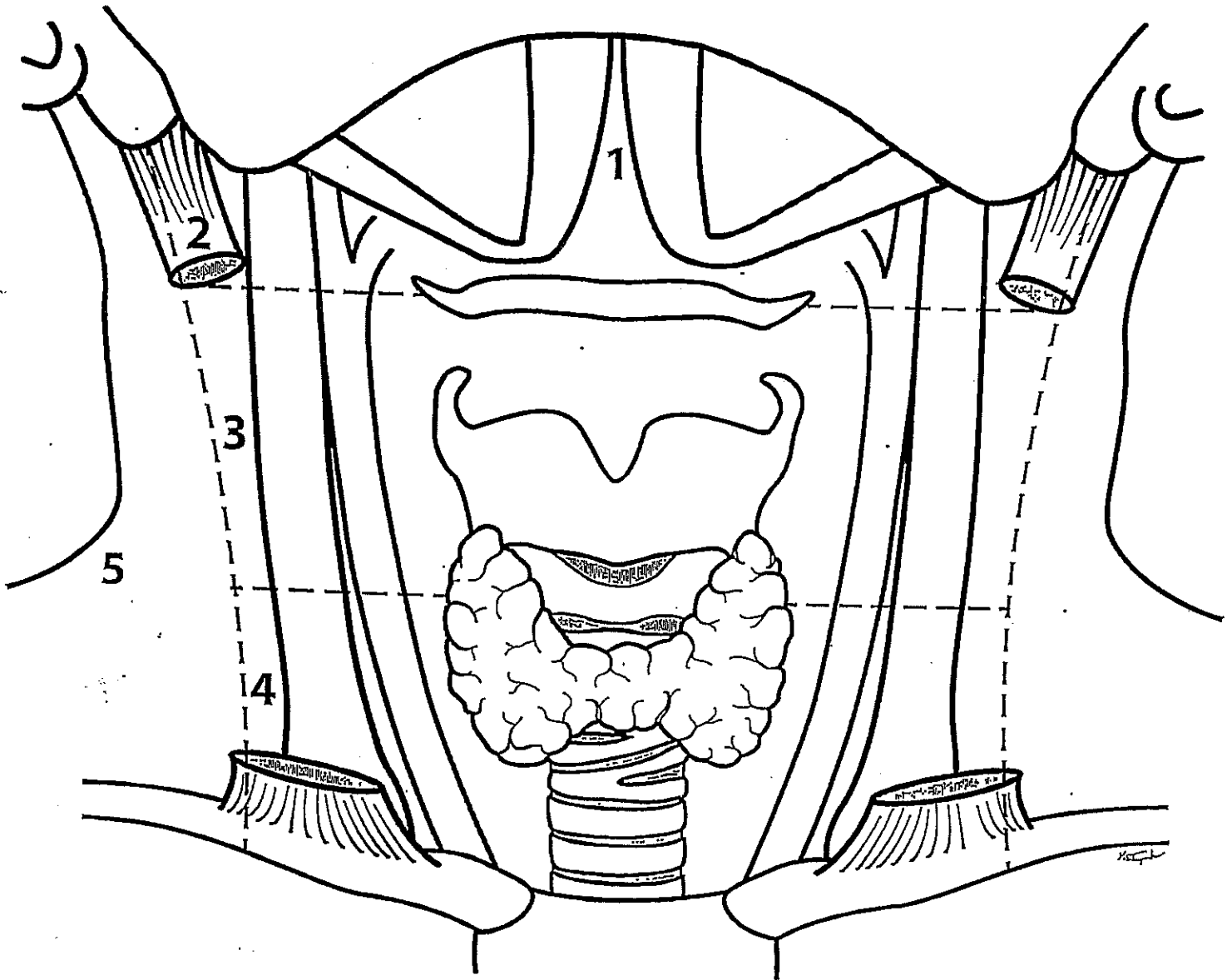
**Ultrasound Criteria for Cervical Nodes**

<b>Ultrasound Criteria</b>	<b>Benign Nodes</b>	<b>Malignant Nodes</b>
Size	< 1 cm	> 1 cm
Shape	Oval kidney bean shape	Round
Long axis/short axis	> 2	< 2
Echogenic hilus	Present	Absent (or eccentric)
Hypoechoic rim	Present, homogeneous	Absent or eccentric widening
Punctuate hyperechoic foci	Absent	Present
Cystic areas	Absent	Present
Vascularity	Central, sparse	Peripheral, irregular

# NECK ULTRASOUND

Patient Name: \_\_\_\_\_ Clinic# \_\_\_\_\_ Date: \_\_\_\_\_

History: \_\_\_\_\_ Exam# \_\_\_\_\_



Impression: \_\_\_\_\_  
\_\_\_\_\_  
\_\_\_\_\_  
\_\_\_\_\_  
\_\_\_\_\_